

Anterior Approach for Multilevel Cervical Disc Prolapse with Spondylotic Myelopathy: Surgical Results, Prognostic Factors and Efficacy of Intraoperative Neuromonitoring

MOHAMED ELHAWARY, M.D.; RAMY TEAMA, M.D. and HANY EL NEMR, M.D.

The Department of Neurosurgery, Faculty of Medicine, Benha University

Abstract

Background: Degenerative cervical myelopathy (DCM) is a nonspecific general term including multiple different components leading to neurological injury of the cervical spinal cord due to both static and dynamic mechanisms of injury both anterior and posterior approaches can be used during surgery according to situation with successful results.

Aim of Study: This retrospective study was carried out with the aim of investigating the operative results and factors affecting outcome for patients with multilevel cervical disc herniation with compressive myelopathy with the use of intraoperative neuro-monitoring.

Patients and Methods: 54 patients with cervical discogenic myelopathy were operated using anterior cervical discectomy and interbody fusion (ACDF). Clinical and radiographic features were reviewed to evaluate the surgical results and prognostic factors. The clinical outcome was judged using two grading systems (Herkowitz's scale and Nurick's grade). Intraoperative neuro-monitoring was used in 32 cases.

Results: Male involvement was more common than female involvement (3:1), C5-6 level was involved in most cases. Difficult walking, variable degree of spasticity, paraesthesia were the most obvious signs. Magnetic resonance (MRI) images showed that central disc herniation was present in all cases with signal changes in the cervical cord in 41 cases. Postoperative, 47 patients showed favourable results (excellent, good) according to Herkowitz's scale. The use of intraoperative neuro-monitoring (IOM) did not produce any significant changes in the outcome regarding postoperative results.

Conclusion: Anterior approach is very efficient for successful surgical treatment of non-traumatic degenerative cervical spondylotic myelopathy affecting multiple levels with satisfactory postoperative results, several factors affect postoperative outcome especially duration of complain and preoperative neurological status. The use of intraoperative neuromonitoring is useless.

Key Words: Cervical disc – Myelopathy – Fusion – Neuro-monitoring.

Correspondence to: Dr. Ramy Teama,
[E-Mail: ramyteama82@gmail.com](mailto:ramyteama82@gmail.com)

Introduction

DEGENERATIVE cervical myelopathy (DCM) is a nonspecific general term including multiple different components such as, ligamentous hypertrophy, calcification of the posterior longitudinal ligament, and cervical disc disease [6]. These different pathologies together constitute the most frequent etiology of degenerative, non-traumatic spinal cord compression in the adults [8]. Degenerative cervical myelopathy is a broad term, representing the advanced age-related degenerative changes of the cervical spine that leads to neurological injury of the cervical spinal cord due to both static and dynamic mechanisms of injury; both anterior and posterior approaches can be used during surgery according to situation with successful results. Neurological injury may occur during surgery for the cervical spine [10]. Some authors recommended the use of intraoperative neuromonitoring (ION) during cervical spine surgery for early detection and avoidance of neurological injury with somatosensory-evoked potentials (SSEPs) to be the most commonly used modality [9]. The objective of this analysis is to evaluate results and prognostic factors of anterior approach for multilevel cervical discogenic compressive myelopathy and identify the benefit from using intraoperative neuromonitoring.

Patients and Methods

Fifty-four patients with cervical disc herniation causing myelopathy were operated on using the anterior approach for excision of cervical discs

Abbreviations:

ACDF : Anterior cervical discectomy and fusion.
DCM : Discogenic cervical myelopathy.
IOM : Intraoperative neuromonitoring.
PLL : Posterior longitudinal ligament.
SSEPs : Somatosensory-evoked potentials.

and interbody fusion in the period from January 2019 to January 2022 at Benha University Hospitals. Intraoperative neuromonitoring was used in 32 cases. Clinical data and radiographic findings were assessed to evaluate the results of surgery and factors affecting the prognosis using two different grading scales (Herkowitz's scale and Nurick's grade). The inclusion criteria for this study were, Patients with multiple level cervical disc prolapse, and Patients had symptoms and signs of myelopathy. Exclusion criteria included patients with Post-traumatic cervical disc prolapse and Ligamentous cervical canal stenosis. Our hospital's medical records were retrospectively reviewed through this period and only 54 patients were selected according to our inclusion criteria, while other patients were excluded due to incomplete contact, clinical, radiological, or follow-up data. The study was approved by the ethical review board at our faculty.

In all patients, standard physical examination was performed including general and neurological examination. The following items were recorded carefully, neck pain, balance difficulties, sensory, bowel/bladder dysfunction and motor power.

In all patients, we performed computed tomography (CT) of the cervical spine for detection of reduction of vertebral canal diameter, osteophytes and possible subluxation. MRI cervical spine is the most important imaging technique for assessment of DCM. MRI allows for assessment of the vertebral body, intervertebral disc degeneration, posterior longitudinal ligament (PLL) abnormalities, in addition to spinal cord morphology and injury, subluxation, suspected instability, or movement-dependent cord compression. Flexion and extension X-rays were useful in some cases for detection of suspected instability.

Surgical technique: The operation was performed under general anaesthesia, in the supine posture, with the aid of an operating microscope, C arm. In our study, we used the anterior cervical approach for cervical discectomy and fusion. In all cases, fusion was done using carbon cages, autologous bone in 17 cases and synthetic bone in 37 cases. Intraoperative neuromonitoring (ION) was used in 32 cases. The aim of surgery was complete microsurgical excision of prolapsed cervical discs and osteophyctomy followed by fusion. We performed surgery for 2 levels in 31 cases and for 3 levels in 23 cases.

Postoperative care: All patients were subjected to clinical assessment after recovery from anesthe-

sia, daily till discharge and at 1, 3, 6 months after discharge then on a yearly basis when ever possible. The follow-up period ranged from 6 months to 24 months. In each visit plain radiographs were done to assess the used cage and the alignment. In each visit, Patients were checked clinically regarding pain, motor power, sphincter, and any new symptoms.

Measures: The clinical outcome was assessed with the aid of two different grading systems [Herkowitz's scale (4) and Nurick's grading (11)]. Herkowitz's scale included 4 categories, excellent (total improvement of pain and weakness), good (improvement of pain and weakness sometimes need analgesia with no lifestyle modification), fair (improvement in pain and weakness requiring analgesia with lifestyle modification), and poor (no improvement in preoperative pain and weakness). We studied the relation between prognosis and different factors like complain duration, preoperative nurick grade and the use of IOM. To study the relation between prognosis and presenting clinical manifestations, we divided patients into two groups based on preoperative Nurick's grade; group (1) favorable prognosis (Nurick's grade 0-3) and group 2 unfavorable prognoses (Nurick's grade 4-5). To study the relation between prognosis and complain duration, we divided patients into two groups based on preoperative duration of complain, group 1 with duration less than 3 months and group 2 with duration more than 3 months. To study the relation between prognosis and the use of IOM, we divided patients into two groups based on the use of IOM. Group 1 in which we used IOM and group 2 in which IOM was not used.

Results

Preoperative clinical and radiological findings:

The age of cases in this study ranged from 38 years to 69 years and the mean age was 47 years with a male to female ratio of (2:1). The mean period of myelopathy duration was 3.2 months. In Table (1) we summarized clinical presentation in this series. The most common clinical findings were difficult walking and spasticity. In Table (2) cases clinical data are presented according to Nurick's grading system.

Regarding Radiology, the least number of levels involved was 2 levels that were recorded in 22 cases (40%), 3 level involvement was recorded in 29 cases (53.7%) and 4 level involvement was recorded in 3 cases (5.5%). C5-6 was the most common involved level in 40 cases (74%), C3-4 was the least involved level, and it was involved

in 3 cases (5.5%). According to the MRI findings, signal alteration within the cord was present in 41 patients. The central location of disc herniation was found in all cases while paracentral disc herniation in levels other than those with central disc herniation was found in 9 cases (16.7%).

Postoperative clinical outcome:

Based on the Herkowitz's scale, excellent outcome was observed in 21 cases, good outcome in 26 patients, fair outcome in 5 patients and poor outcome in 2 cases.

Relation between postoperative outcome and preoperative Nurick's grade:

There was a remarkable relationship between pre-operative Nurick's grade and Herkowitz's outcome, based on preoperative Nurick's grade; group (1) (Nurick's grade 0-3) had better outcome than group 2 (Nurick's grade 4-5) (Table 3).

Table (1): Clinical findings in 54 cases with compressive myelopathy due to herniated cervical discs.

Clinical findings	No. of cases (%)
Walking Difficulties	42 (77.7%)
Spasticity	30 (55.6%)
Paraesthesia	24 (44.5%)
Radiculopathy	18 (33.3%)
Muscle wasting	15 (27.8%)
Sphincter disturbances	12 (22.2%)
Central cord syndrome	9 (16.7%)

Table (2): Cases clinical data are presented according to Nurick grading system.

Nurick grading system	Case number (%) (54=100%)	Description
0	2	Only root symptoms
1	10	Signs of cord involvement, normal gait
2	23	Mild gait abnormality, employed
3	14	More gait abnormality, un employed
4	5	Can be ambulated with aid
5	0	Chair bound, bedridden

Table (3): Relation between pre-operative Nurick's grade and postoperative outcome according to Herkowitz's scale.

Group	Preop. Nurick's grade	Excellent-good outcome
1	0~3 (n:49)	45 (92%)
2	4~5 (n:5)	2 (40%)

Relation between postoperative outcome and complain duration:

There was a remarkable relation between complain duration and outcome, the shorter the duration of symptoms the better the postoperative outcome.

Relation between postoperative outcome and the use of neuromonitoring:

The use of intraoperative neuromonitoring did not produce any significant changes in the postoperative outcome. We used intraoperative neuromonitoring in 32 cases (60%); excellent-good outcome was recorded in 28 cases (87%). Intraoperative neuromonitoring was not used in 22 cases (40%); excellent-good outcome was recorded in 19 cases (86%).

Postoperative complications:

Postoperative mild complications were recorded in 8 cases including postoperative radiculopathy in one case, postoperative hematoma in two cases, postoperative wound infection in one case, postoperative hoarseness of voice in two cases and postoperative dysphagia in two cases which was improved in 2 months (Table 5). All of these complications were managed using conservative treatment and were improved within a reasonable time.

Table (4): Relation between complain duration and postoperative outcome.

Group	Duration	Excellent-good outcome
1	<3 months (44 cases)	42 (95%)
2	>3 months (10 cases)	5 (50%)

Table (5): Postoperative complications.

Postoperative complications	Number of cases
Radiculopathy	1
Hematoma	2
Wound infection	1
Dysphagia	2
Hoarseness of voice	2

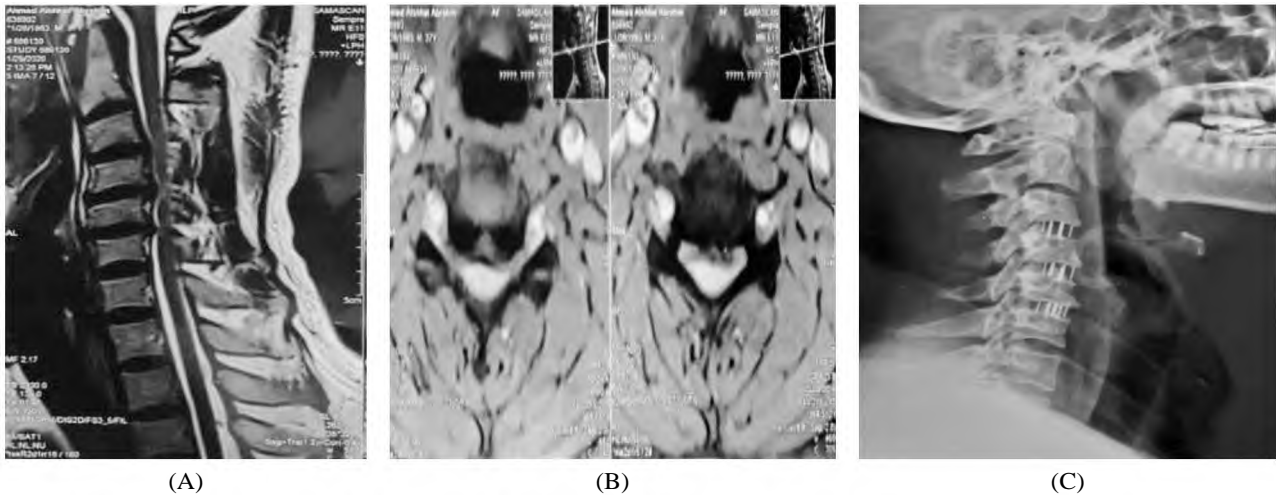


Fig. (1): MRI cervical spine sagittal (A) and Axial (B) Views showing multiple levels cervical disc prolapse (3 levels) with cord signal and postoperative X-ray lateral view (C) After surgery for 3 levels. In axial views C3-4 shows left paracentral disc herniation while C4-5 shows central disc herniation.

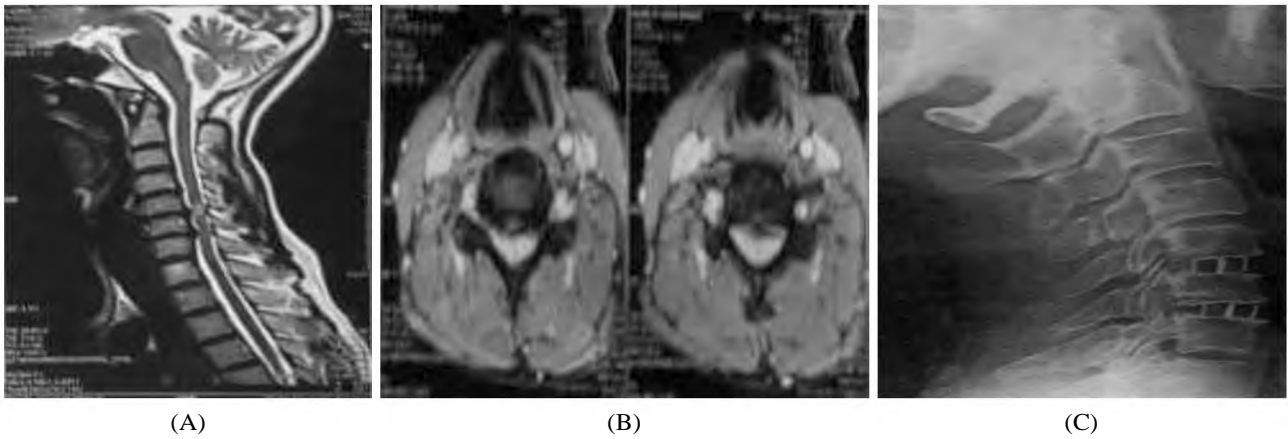


Fig. (2): MRI cervical spine sagittal (A) and Axial (B) Views showing multiple cervical discs prolapse (2 levels) with cord signal and postoperative X-ray lateral view (C).

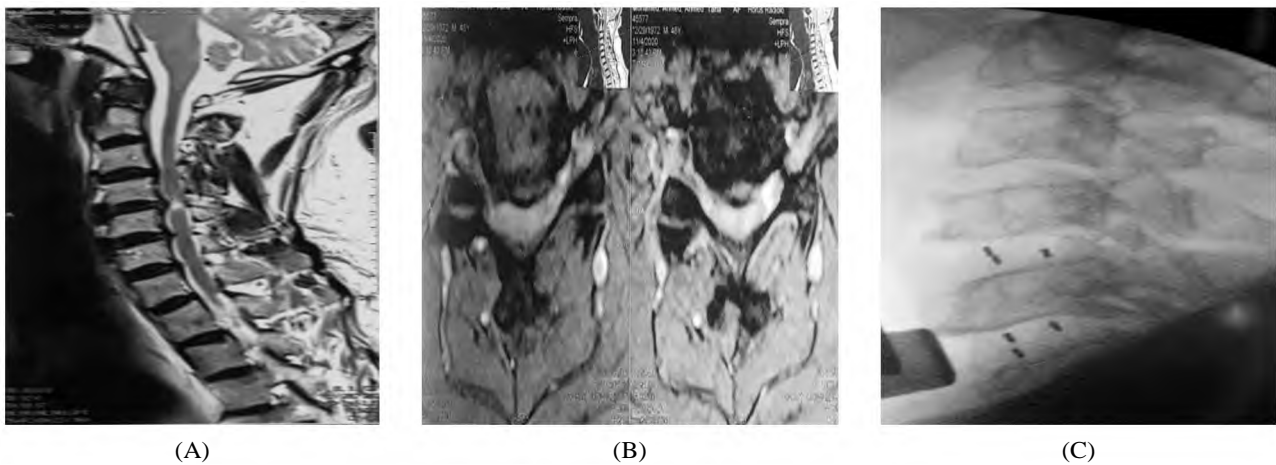


Fig. (3): MRI cervical spine sagittal (A) and Axial (B) Views showing multiple cervical discs prolapse with ischemic cord signal (4 levels) and intraoperative X-ray lateralview after surgery for 2 levels.

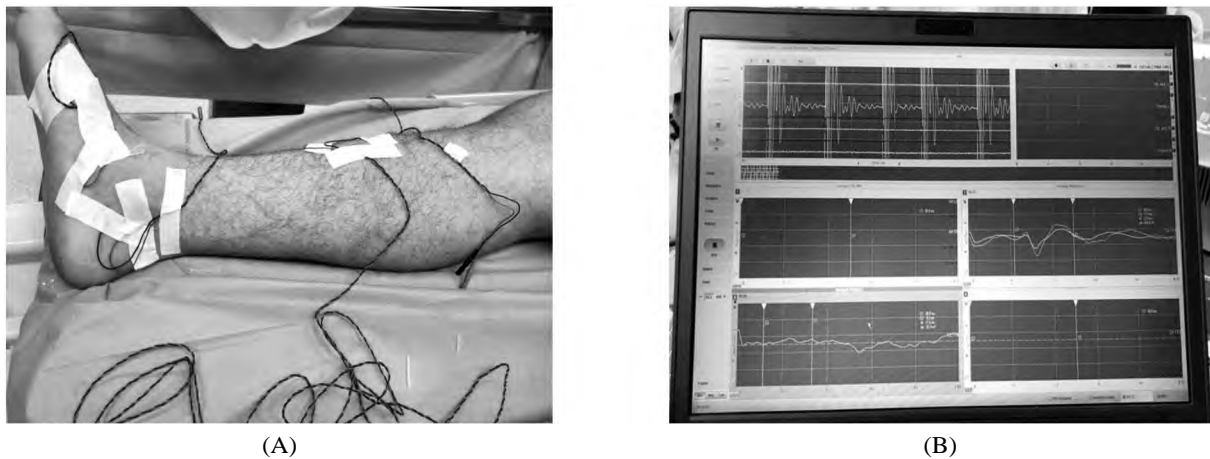


Fig. (4): Patient's lower limb with leads of neuro-monitoring (A) and the monitor of the neuro-monitoring device (B).




Fig. (5): MRI cervical spine sagittal (A) and Axial (B) Views showing multiple cervical discs prolapse (3 levels) with cord signal, and postoperative x-ray lateral view (C) After ACDF for 3 levels.

Discussion

Degenerative cervical disc prolapse with evident myelopathy is considered a surgical challenge, about 30 to 65 % of patients show deterioration within 3 to 6 years if conservative management is employed [5]. In the same time, asymptomatic cases with radiological evidence of cord compression develop symptoms in about 8% during 1 year and about 23% during 4 years of clinical observation [13].

Kim et al., performed a study including 26 cases to show the results of surgical intervention in cases of myelopathy caused by soft cervical disc herniation, in this study, male involvement was much more common than female involvement and the most common clinical complaint was disturbed gait and spasticity which is the same as our study, in this study the authors also used Herkowitz's scale for grading the surgical results as well. In this study the authors confirmed that shorter dura-

tion of complain and better preoperative clinical status are the most important factors affecting surgical outcome which conforms to our results [7].

In the study performed by Park et al., the authors concluded that longer duration of complain more than 1 month is associated with better outcome which is the opposite to our study and to the study performed by Kim et al., but they agree with us and Kim et al., in the relation between preoperative complain and postoperative outcome that less severe preoperative complain is associated with better postoperative outcome [12].

Surgical approaches to decompress the cervical spinal cord are used with the goal of elimination of the offending compressive agent and providing more space for the cervical spinal cord. In our study we preferred to use anterior cervical discectomy with interbody fusion which was an effective approach to decompress the cervical cord with low

risks which is compatible with the results in the study performed by Park et al., [12] and Bin et al., [2]. Anterior approaches for cervical spondylotic myelopathy are usually employed in cases with kyphosis or in cases with mainly compressive anterior pathology so we used anterior cervical discectomy with interbody fusion in all cases, in a study made by Wu et al., the authors recommended using ACDF as it can provide multiple points of distraction and so induce cervical lordosis [15].

In our study, the use of intraoperative neuromonitoring was not of great value to give better results for ACDFs as compared to patients operated without intraoperative neuromonitoring. In a study performed by Bose et al., there was no significant difference in surgical results after ACDF with or without ION [3].

Ajiboye et al., performed a retrospective study to evaluate the role of intraoperative neuromonitoring in ACDF including 15,395 cases. The authors concluded that the use of ION has decreased so much because it has no value in such cases and doesn't affect the postoperative outcome. The authors also found that the use of ION has been decreased from 22.8% in the year of 2007 to 4.3% use in the year of 2014 [1].

The incidence of postoperative complications in our study was 14.7% which is close to the incidence reported in most literature, the complications were in the form of minor complications including post-operative radiculopathy in one case (1.8%), postoperative hematoma in two cases (3.7%), wound infection in one case (1.8%), hoarseness of voice in 2 cases (3.7%) and dysphagia in 2 cases (3.7%). Tasiou et al., performed a retrospective study to evaluate complications related to anterior cervical approaches and specify the predisposing factors. This study included traumatic cases and degenerative cases in addition to cases with myelopathy or radiculopathy caused by disc herniation, the overall number of cases was 114. The surgical procedure included ACDF or corpectomy. The complication rate was 13.2%, the complications were adjacent segment disease in 2.7% of their cases, dysphagia in 1.7%, soft tissue swelling and hematoma in 1.7%, and dural injury in 1.7%, perforation of the esophagus was present in 0.9%, exaggeration of the already present myelopathy in 0.9%, symptomatic recurrent laryngeal nerve injury in 0.9%, implant failure in 0.9%, and superficial-wound infection in 0.9% [14].

Conclusion:

Anterior approach is very efficient for successful surgical treatment of non-traumatic degenerative

cervical spondylotic myelopathy affecting multiple levels with satisfactory postoperative results, several factors affect postoperative outcome especially duration of complain and preoperative neurological status. The use of intraoperative neuromonitoring is useless.

References

- 1- AJIBOYE R.M., D'ORO A., ASHANA A.O., BUERBA R.A., LORD E.L. and BUSER Z.: Routine Use of Intraoperative Neuromonitoring During ACDFs for the Treatment of Spondylotic Myelopathy and Radiculopathy Is Questionable. *Spine (Phila Pa 1976)*, 42 (1): 14-19, 2017.
- 2- BIN ZHU, YILAN XU, XIAOGUANG LIU, ZHONGJUN LIU and GENGTING DANG: Anterior approach versus posterior approach for the treatment of multilevel cervical spondylotic myelopathy: A systemic review and meta-analysis. *Eur. Spine J.*, 22 (7): 1583-1593, 2013.
- 3- BOSE B., SESTOKAS A.K. and SCHWARTZ D.M.: Neurophysiological monitoring of spinal cord function during instrumented anterior cervical fusion. *Spine J.*, 4: 202-7, 2004.
- 4- HERKOWITZ H.N., KURZ L.T. and OVERHOLT D.P.: Surgical management of cervical soft disc herniation. A comparison between the anterior and posterior approach. *Spine*, 15: 1026-1030, 1990.
- 5- HOSONO N., SAKAURA H., MUKAI Y., KAITO T., MAKINO T. and YOSHIKAWA H.: A simple performance test for quantifying the severity of cervical myelopathy. *J. Bone Joint Surg. Br.*, 90 (9): 1210-3, 2008.
- 6- KARADIMAS S.K., GATZOUNIS G. and FEHLINGS M.G.: Pathophysiology of cervical spondylotic myelopathy. *Eur. Spine J.*, 24 (Suppl 2): 132-8, 2015.
- 7- KIM Y.D., OH S.H., YI H.J., KIM Y.S., KO Y. and OH S.J.: Myelopathy Caused by Soft Cervical Disc Herniation: Surgical Results and Prognostic Factors. *J. Korean Neurosurg. Soc.*, 42: 441-445, 2007.
- 8- MORISHITA Y., NAITO M., HYMANSON H., MIYAZAKI M., WU G. and WANG J.C.: The relationship between the cervical spinal canal diameter and the pathological changes in the cervical spine. *Eur. Spine J.*, 18 (6): 877-883, 2009.
- 9- NOURI A., MONTEJO J., SUN X., VIROJANAPA J., KOLB L.E., ABBED K.M., et al.: Cervical Cord-Canal Mismatch: A New Method for Identifying Predisposition to Spinal Cord Injury. *World Neurosurg*, 108: 112-117, 2017.
- 10- NOURI A., TETREAU L., SINGH A., KARADIMAS S.K. and FEHLINGS M.G.: Degenerative Cervical Myelopathy: Epidemiology, Genetics, and Pathogenesis. *Spine (Phila Pa 1976)*, 40 (12): E675-93, 2015.
- 11- NURICK S.: The natural history and the results of surgical treatment of the spinal cord disorder associated with cervical spondylosis. *Brain*, 95: 101-108, 1972.
- 12- PARK S.J., KIM S.B., KIM M.K., LEE S.H. and OH I.H.: Clinical Features and Surgical Results of Cervical Myelopathy Caused by Soft Disc Herniation. *Korean J. Spine*, 10 (3): 138-43, 2013.

- 13- RHEE J.M., HEFLIN J.A., HAMASAKI T. and FREEDMAN B.: Prevalence of physical signs in cervical myelopathy: A prospective, controlled study. Spine (Phila Pa 1976), 34 (9): 890-5, 2009.
- 14- TASIOU A., GIANNIS T., BROTIAS A., SIASIOS I., GEORGIADIS I., GATOS H., et al.: Anterior cervical spine surgery-associated complications in a retrospective case-control study. J. Spine Surg., 3 (3): 444-459, 2017.
- 15- WU J.C., KO C.C., YEN Y.S., HUANG W.C., CHEN Y.C., LIU L., et al.: Epidemiology of cervical spondylotic myelopathy and its risk of causing spinal cord injury: A national cohort study. Neurosurg Focus, 35 (1): E10, 2013.

النهج الأمامي لتدلي القرص العنقي متعدد المستويات مع اعتلال النخاع الفقاري النتائج الجراحية والعوامل الإنذارية وفعالية وفعالية المراقبة العصبية أثناء العملية

بيانات الخلفية : الاعتلال النخاعي العنقي التنكسي هو مصطلح عام غير محدد يشمل عدة مكونات مختلفة مثل، تضخم الأربطة، تكلس الرباط الطولى الخلفي، ومرض القرص العنقي الذي يؤدي إلى إصابة عصبية في الحبل الشوكي العنقي. ويمكن علاجه جراحياً باستخدام النهج الأمامي أو الخلفي.

الهدف من الدراسة : أجريت هذه الدراسة بأثر رجعي بهدف التحقق من نتائج العملية والعوامل التي تؤثر على النتيجة للمرضى الذين يعانون من فتق القرص العنقي متعدد المستويات مع اعتلال النخاع الانضغاطي باستخدام المراقبة العصبية أثناء العملية.

المرضى والطرق : تم إجراء جراحة لعدد ٥٤ مريضاً يعانون من اعتلال النخاع العنقي متعدد المستويات باستخدام استئصال القرص العنقي الأمامي والدمج بين الجسمين. تمت مراجعة السمات السريرية والشعاعية لتقييم النتائج الجراحية والعوامل الإنذارية. تم الحكم على النتائج السريرية باستخدام نظامين للدرجات (مقياس هيركوفيتز ودرجة نوريك). تم استخدام المراقبة العصبية أثناء العملية في ٣٢ حالة.

النتائج : كان عدد الذكور ضعف عدد الإناث (١:٣)، وكان C5-6 هو المستوى الأكثر مشاركة. كان المشي الصعب، ودرجات متفاوتة من التصلب العضلي هي العلامات الأكثر وضوحاً. أظهرت صور الرنين المغناطيسي (MR) أنه تم الكشف عن فتق القرص المركزي في جميع الحالات وتغييرات إشارة الحبل المصاحبة في ٤١ حالة. بعد الجراحة، أظهر ٤٧ مريضاً نتائج إيجابية (ممتازة، جيدة) وفقاً لمقياس هيركوفيتز. لم ينتج عن استخدام المراقبة العصبية أثناء العملية أى تغييرات مهمة في النتيجة فيما يتعلق بالمضاعفات العصبية بعد الجراحة.

الخلاصة : النهج الأمامي فعال للغاية في العلاج الجراحي الناجح للاعتلال النخاعي الفقاري الرقبى التنكسي غير الرضحي الذي يؤثر على مستويات متعددة مع نتائج مرضية بعد الجراحة، وتؤثر عدة عوامل على نتائج ما بعد الجراحة وخاصة مدة الشكوى والحالة العصبية قبل الجراحة.